

THORACIC LIMB

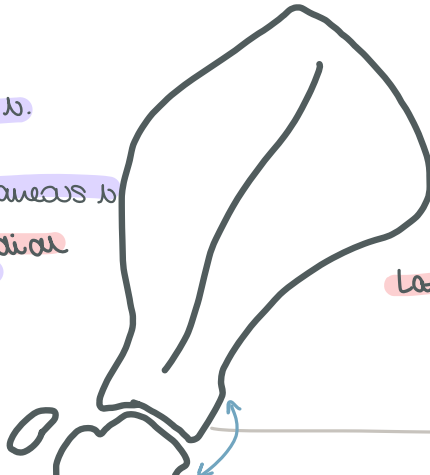Shoulder

adduct/extend shoulder
 subscapularis - subscapular N.
 coracobrachialis - musculocutaneous N.
 flex shoulder - teres major - Axillary N.

extend shoulder [supraspinatus] suprascapular N.

flex/extend + abduct [infraspinatus]

flex shoulder [deltoidus teres minor] Axillary N.



lateral

Brachium

flex elbow
 biceps brachii (also extend shoulder) musculocutaneous N.
 brachialis

tensor fasciae antibrachii

triceps brachii

• long • lateral
 • accessory • medial

Radial N.

anconeus

extend elbow

caudal

cranial

* long head also flexes shoulder

Antebrachium

extend carpus + digits
 Extensor carpi radialis
 Common digital extensor
 Lateral digital extensor
 Ulnaris lateralis

Radial N.

cranio lateral

pronate paw

Pronator quadratus
 Pronator teres

Median N.

caudo medial

flex carpus + digits

Flexor Carpi Radialis
 Superficial digital flexor
 Deep digital flexor
 Flexor Carpi Ulnaris

Ulnar N.

supinate paw - Supinator

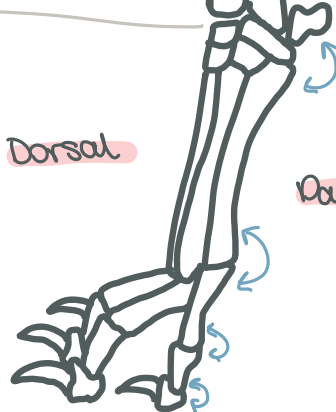
abduct digit I - Abductor

M manus

flex metacarpo phalangeal joints - interosseus - Ulnar N.

Dorsal

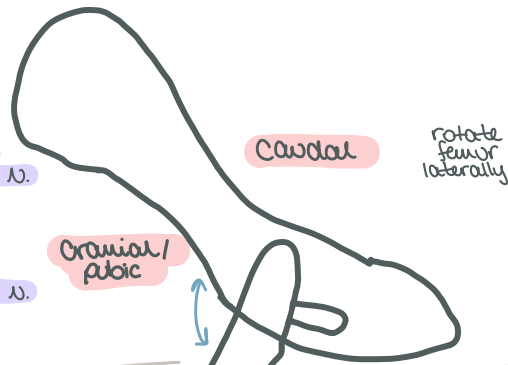
Volar



pelvic limb

Hip

- hip flexors
- iliopsoas - lumbar N. + femoral N.
 - tensor fascia latae
- extend + abduct hip
- middle gluteal - Cranial Gluteal N.
 - deep gluteal - Cranial Gluteal N.
 - superficial gluteal - Caudal Gluteal N.



- internal obturator
- gemelli - Sciatic N.
- quadratus femoris (also extends hip)
- external obturator

Thigh

- extend stifle
- quadriceps femoris
 - rectus fem.
 - vastus lateralis
 - vastus intermedius
 - vastus medialis
- femoral N.

Cranial

- flex hip - sartorius - saphenous N. + femoral N.
- adduct limb
- gracilis
 - pectineus - obturator N.
 - adductor

medial

- extend hip
- biceps femoris
 - semitendinosus - Sciatic N.
 - semimembranosus

caudal

* form the common calcaneal tendon

Crus

- flex tarsus
- long digital extensor (& extend digits)
 - peroneus longus (rotate paw)
- extend digits
- lateral digital extensor
- Peroneal N.*

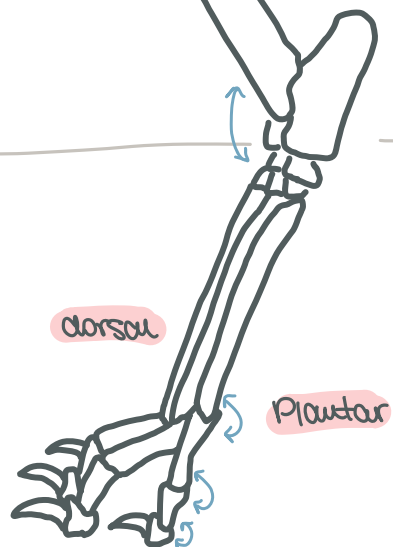
caudal

Cranio lateral

- flex stifle
- gastrocnemius
 - superficial digital flexor (& flex digits)
 - deep digital flexor (& flex digits)
- extend tarsus
- Popliteus - rotate leg medially
- tibial N.

* Long is deep peroneal
P is common peroneal
lat is superficial peroneal

Pes



- gastrocnemius - tibial N.
- connects down here as part of common calcaneal tendon